

## Neurocysticercosis Presenting as Myoclonus: A Rare Manifestation

Amruta A. Gokhale\*, Milind S. Tullu\*\*, Mukesh Agrawal\*\*\*, Vrushabh S. Gavali\*\*\*\*

### Abstract

Neurocysticercosis manifesting with movement disorders is quite uncommon in children. Herein, we report a case of neurocysticercosis in an eight-year-old boy who presented with myoclonus. Magnetic resonance imaging of the brain revealed a solitary neurocysticercosis lesion in the left frontal lobe. The child improved within two days of starting albendazole and prednisolone (for the neurocysticercosis). Occurrence of myoclonus in neurocysticercosis has been discussed in this report.

**Keywords:** Albendazole; Brain; Cortical; Frontal Lobe; Myoclonus; Magnetic Resonance Imaging; Neurocysticercus; Taenia Solium.

### Introduction

Neurocysticercosis (NCC) is an important cause of focal seizures in the Indian subcontinent and can present with seizures, symptoms of raised intracranial pressure as well as focal neurological deficits [1-7]. Occurrence of movement disorders due to neurocysticercosis is very rare [3, 8]. We report a very rare presenting manifestation (i.e. myoclonus) of neurocysticercosis in an eight-year-old male child.

### Case Report/Case Summary

An eight-year-old male child presented with complaints of flinging movements of right upper and lower limb for seven days prior to the hospital admission. The movements did not have any exaggerating or relieving factors and showed no diurnal variation. The movements were present throughout the day including during sleep. There was no history of fever. The parents did not give any history of scholastic backwardness or seizures.

On clinical examination, the movements were consistent with myoclonus. Neurologic examination was essentially normal except for brisk deep tendon reflexes in lower limbs and bilateral ankle clonus. The child was investigated for Rheumatic fever (antistreptolysin O titre, electrocardiogram, chest radiograph and 2D-echocardiography), Wilson's disease (serum ceruloplasmin and slit lamp examination for Kayser-Fleischer ring on cornea), and Autoimmune diseases (anti-nuclear antibody titre), but this work-up was essentially normal. The patient's serum electrolytes, serum calcium, phosphorus, creatinine, liver function tests, blood glucose levels, complete blood count and ultrasonography of abdomen were also normal. There was no history of any drug intake (like antidepressants, levodopa, phenytoin, etc.) which can cause involuntary movements.

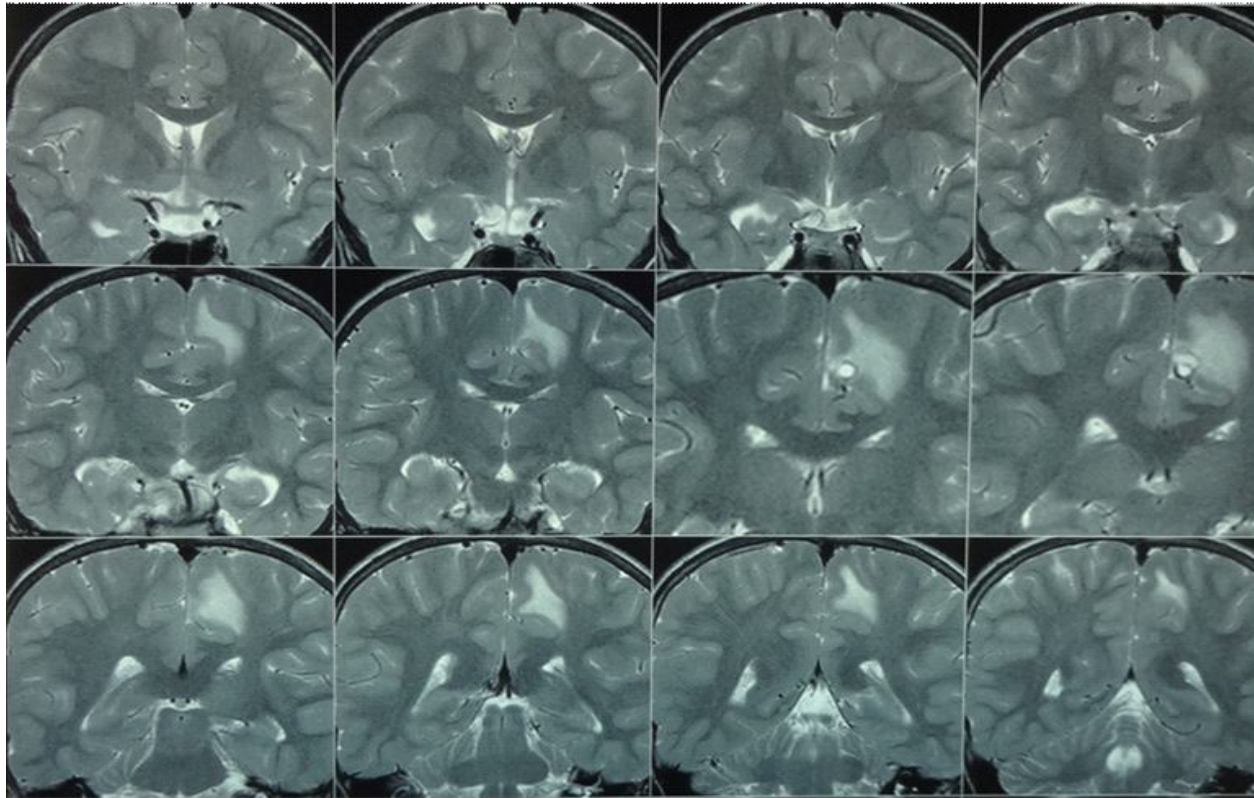
The magnetic resonance imaging of the brain revealed a lesion with mixed signal intensity in left high frontal gyrus on T2 weighted studies with perilesional edema showing suppression on FLAIR images. Diffusion studies did not reveal restricted diffusion. A focal area in the lesion showed high T2 signal with corresponding rim enhancement on post-contrast scans. No other focal or generalized lesion was seen in the brain. These imaging findings were consistent with a diagnosis of neurocysticercosis (Fig.1). Magnetic resonance imaging of the spine was normal. Electroencephalogram did not reveal any epileptogenic focus. The patient was started on treatment with albendazole and oral prednisolone. The patient improved within two days with disappearance of the myoclonus and was discharged.

**Author Affiliation:** \*MD Registrar; \*\*MD, DCH, DNB, FCPS, MNAMS, FIAP Professor- Additional; \*\*\*MD Professor & Head; \*\*\*\*MD Registrar. Department of Pediatrics, Seth G.S. Medical College and KEM Hospital, Mumbai 400012, Maharashtra, India

**Reprint request:** Milind S. Tullu, "Sankalp Siddhi", Block No.1, Ground floor, KherNagar, Service Road, Bandra (East), Mumbai 400051, Maharashtra, INDIA.

E-mail: milindtullu@yahoo.com

**Fig. 1:** Magnetic resonance imaging (T2 weighted images) showing focal lesion in left high frontal region (suggesting neurocysticercosis)



## Discussion

Neurocysticercosis is a parasitic infection of the central nervous system acquired through ingestion of the eggs of the pork tapeworm (*Taenia solium*) [2, 8]. The egg releases oosphere in the intestine which crosses the gut wall, spreads hematogenously to many tissues including brain and produce small fluid filled bladders containing a single protoscolex. In the central nervous system, the cysts are mainly found in the cortical and subcortical areas [3, 8].

Focal neurological findings are related to the size, number, and location of the neurocysticercosis [1, 3, 8]. The presenting features (of neurocysticercosis) include seizures, headache, focal neurological deficits, raised intracranial pressure with or without hydrocephalus, neuropsychiatric/ neuropsychological disorders, etc [1, 3, 4, 7, 8]. Uncommon presentations include mesencephalic syndrome, dorsal midbrain syndrome, ptosis, papillitis, cervical radiculopathy, cerebral hemorrhage, paraplegia, dystonia, aphasia, etc [1, 8]. Extrapyramidal signs and symptoms in patients with neurocysticercosis have not been reported and this may be due to small size of the cysts, their slow growth, or adaptation to host tissue [3, 8].

Movements disorders due to neurocysticercosis are rare, have been mainly reported in adults and include hemichorea, hemiballismus, dystonia, parkinsonism and rarely myoclonus [1, 3, 8, 9]. Movement disorders can result from one of these three mechanisms: inflammatory reaction following death of parasite, mass effect of a large cyst or effects of antiparasitic therapy [3, 8].

Myoclonus is a movement disorder, which presents itself with sudden, brief and shock-like jerks which can be divided into cortical, subcortical, spinal and peripheral (based on the presumed source of its generation) [9, 10, 11]. Cortical myoclonus is the most common form of myoclonus and mainly affects the distal upper limbs and face [10]. Focal cortical myoclonus points to a lesion of the sensorimotor cortex with hyper-excitability (due to vascular, inflammatory or neoplastic cause) [10]. Focal and multifocal jerks are typical of cortical myoclonus [10].

Our patient had a focal cortical myoclonus due to the inflammatory etiology, which in our case was neurocysticercosis in the frontal paramedian location. Movement disorders are known to develop due to lesions in frontal lobe as explained by fronto-subcortical connections [12]. Our patient was treated with oral steroids (oral prednisolone 2mg/kg/day)

for 5 days followed by anti-helminthic treatment (albendazole 15 mg/kg/day), but he actually improved within two days. This can partly be explained by the natural resolution of the perilesional edema. A similar Pediatric patient of neurocysticercosis manifesting as myoclonus has been reported by Puri *et al.* (1991) in an 11-year-old female manifesting only as myoclonic seizures; wherein the diagnosis was based upon the enzyme-linked immune-sorbent assay, computed tomography and biopsy of a subcutaneous nodule [9]. The patient was treated with sodium valproate and two courses of praziquantel [9].

Neurocysticercosis should be kept in mind when confronted with any neurological manifestation in patients residing in endemic areas [13]. The current Pediatric case of solitary neurocysticercosis (manifesting as non-epileptic myoclonus) highlights the need to consider neurocysticercosis in the differential diagnosis of a patient presenting with unilateral myoclonus, particularly when the patient is from areas endemic for neurocysticercosis.

#### What is known?

Movement disorders are a rare presenting feature of neurocysticercosis.

#### What is new/What does this report add?

Myoclonus can be a presenting manifestation of neurocysticercosis in children.

#### References

1. Sawhney IM, Singh G, Lekhra OP, Mathuriya SN, Parihar PS, Prabhakar S. Uncommon presentations of neurocysticercosis. *J Neurol Sci.* 1998; 154(1): 94-100.
2. Rosenfeld E. Neurocysticercosis update. *Pediatr Infect Dis J.* 2003; 22(2): 181-182.
3. Cosentino C, Velez M, Torres L, Garcia HH, Cysticercosis Working Group in Peru. Cysticercosis lesions in basal ganglia are common but clinically silent. *Clin Neurol Neurosurg.* 2002; 104(1): 57-60.
4. Carpio A. Neurocysticercosis: an update. *Lancet Infect Dis.* 2002; 2(12):751-762.
5. McCormick GF. Cysticercosis: review of 230 patients. *Bull Clin Neurosci.* 1985; 50: 76-101.
6. Rosenfeld EA, Byrd SE, Shulman ST. Neurocysticercosis among children in Chicago. *Clin Infect Dis.* 1996; 23(2): 262-268.
7. Singhi P, Ray M, Singhi S, Khandelwal N. Clinical spectrum of 500 children with neurocysticercosis and response to albendazole therapy. *J Child Neurol.* 2000; 15(4): 207-213.
8. Karnik PS, Tullu MS, David JJE, Ghildiyal RG. Neurocysticercosis-induced hemiballismus in a child. *J Child Neurol.* 2011; 26(7): 904-906.
9. Puri V, Chowdhury V, Gulati P. Myoclonus: a manifestation of neurocysticercosis. *Postgrad Med J.* 1991; 67(783):68-69.
10. Kojovic M, Cordivari C, Bhatia K. Myoclonic Disorders: a practical approach for diagnosis and treatment. *Therapeutic Advances in Neurological Disorder.* 2011; 4(1): 47-62.
11. Caviness JN, Brown P. Myoclonus: current concepts and recent advances. *Lancet Neurol.* 2004; 3(10): 598-607.
12. Cummings JL. Frontal-subcortical circuits and human behavior. *Arch Neurol.* 1993; 50(8): 873-880.
13. Carabin H, Ndimubanzi PC, Budke CM, Nguyen H, Qian Y, Cowan LD, Stoner JA, Rainwater E, Dickey M. Clinical manifestations associated with neurocysticercosis: a systematic review. *PLoS Negl Trop Dis.* 2011; 5(5): e1152.

## Indian Journal of Trauma and Emergency Pediatrics

### Library Recommendation Form

If you would like to recommend this journal to your library, simply complete the form below and return it to us. Please type or print the information clearly. We will forward a sample copy to your library, along with this recommendation card.

#### Please send a sample copy to:

Name of Librarian

Library

Address of Library

#### Recommended by:

Your Name/ Title

Department

Address

#### Dear Librarian,

I would like to recommend that your library subscribe to the **Indian Journal of Trauma and Emergency Pediatrics**. I believe the major future uses of the journal for your library would be:

1. useful information for members of my specialty.
2. an excellent research aid.
3. an invaluable student resource.

I have a personal subscription and understand and appreciate the value an institutional subscription would mean to our staff.

Should the journal you're reading right now be a part of your University or institution's library? To have a free sample sent to your librarian, simply fill out and mail this today!

Stock Manager

#### Red Flower Publication Pvt. Ltd.

48/41-42, DSIDC, Pocket-II, Mayur Vihar, Phase-I

Delhi - 110 091 (India)

Tel: 91-11-22754205, 45796900, Fax: 91-11-22754205

E-mail: redflowerppl@gmail.com, redflowerppl@vsnl.net

Website: www.rfppl.co.in